

**HACETTEPE UNIVERSITY**  
**DEPARTMENT OF GASTROENTEROLOGY**

**COLONOSCOPY REPORT**

**Informations:**

**Patient's File ID:** 2123231  
**Name-Surname:** George Clement  
**Age:** 54  
**Sex:** M  
**Date of Procedure:** 13-Eylül-2010  
**Physician:** Professor Doctor , M.D.  
**Indication:** Blood in stool  
**Preparation:** Injection, ECG  
**Premedication:** Dormicum IV

a: Anal Canal

Image 1

**Findings:**

**Anal Canal:** Normal  
**Rectum:** Normal  
**Sigmoid:** Normal  
**Decending Colon:** Normal  
**Splenic Flexure:** Normal  
**Transverse Colon:** Normal  
**Hepatic Flexure:** Normal  
**Ascending Colon:** Normal  
**Cecum:** Suspected lesion. 2x1 cm in diamether  
**I.C. Valve:** Normal  
**Ileum:** Normal

b: Rectum

Image 2

**Results:**

**Biopsy:** Taken from the lesion at cecum  
**Complication:** No  
**Impression:** Suspected lesion at cecum

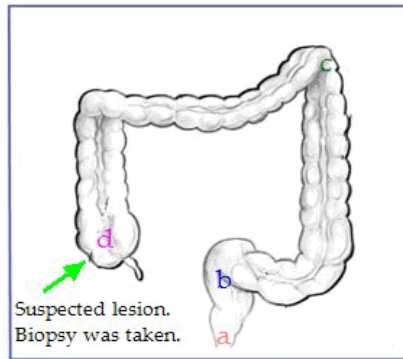
c: Splenic Flexura

Image 3

**Plan:** Wait for the result of the biopsy

d: Cecum

Image 4



**Signature:**

Professor Doctor , M.D.