

HACETTEPE UNIVERSITY
DEPARTMENT OF GASTROENTEROLOGY

UPPER GI ENDOSCOPY REPORT

Informations:

Patient's File ID: 2123231
Name-Surname: George Clement
Age: 54
Gender: M
Date of Procedure: 13-Eylül-2010
Physician: Professor Doctor , M.D.
Indication: Gastric pain
Preparation: IV, ECG, Sedation
Premedication: Dormicum IV

a:

Image 1

Findings:

Oropharynx: Normal
Esophagus: Normal
EG Junction: Normal
Cardia: Normal
Fundus: Normal
Body: Normal
Antrum: Normal
Pylorus: Normal
Duodenum Bulb: Ulcerations
2. Portion: Normal
3. Portion: Normal

b:

Image 2

Results:

Biopsy: Not taken
Complication: No
Impression: Peptic ulcerus

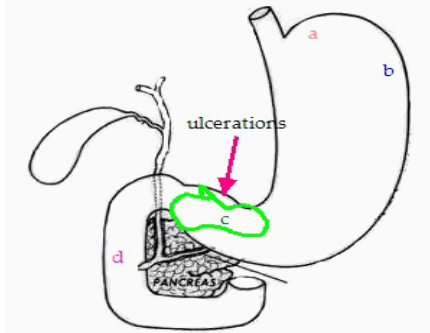
c:

Image 3

Plan: Medication, wait for H.Pylori

d:

Image 4



Signature:

Professor Doctor , M.D.